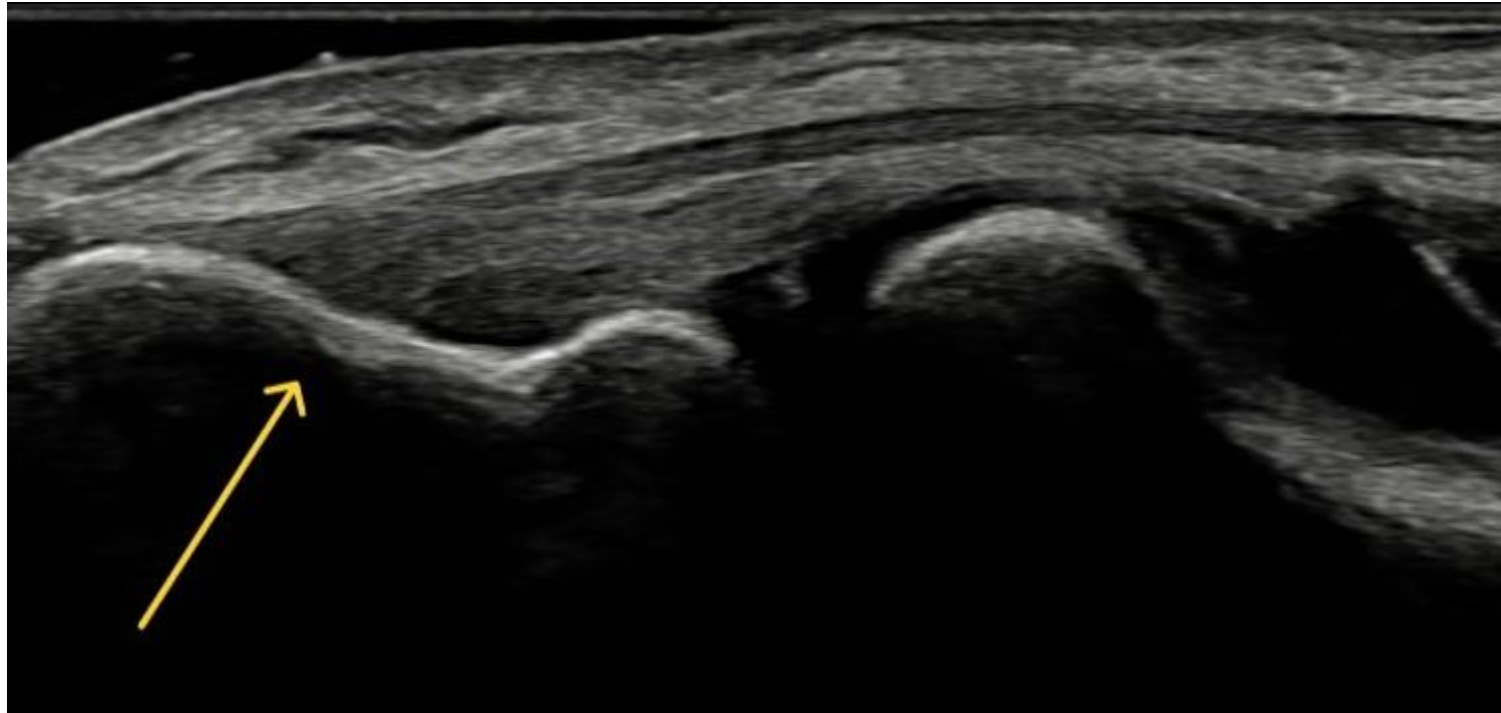


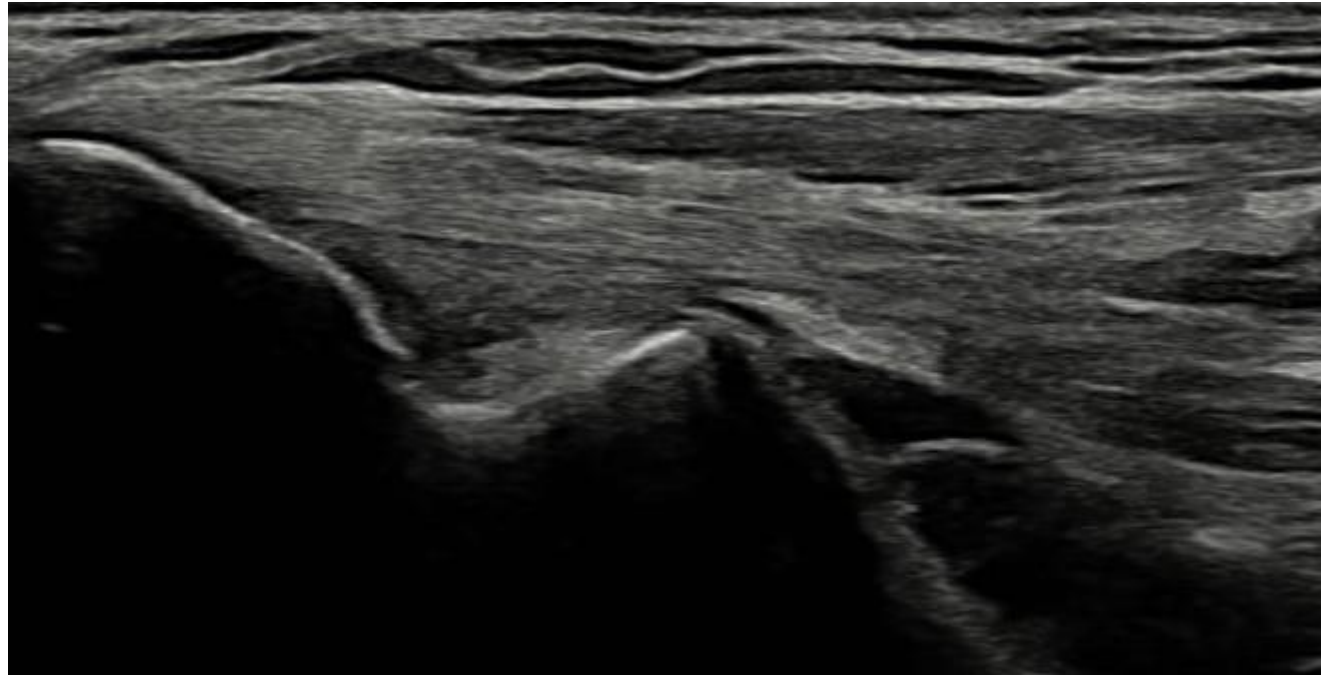
Laterale albue

Felles ekstensorsene og laterale epikondyl



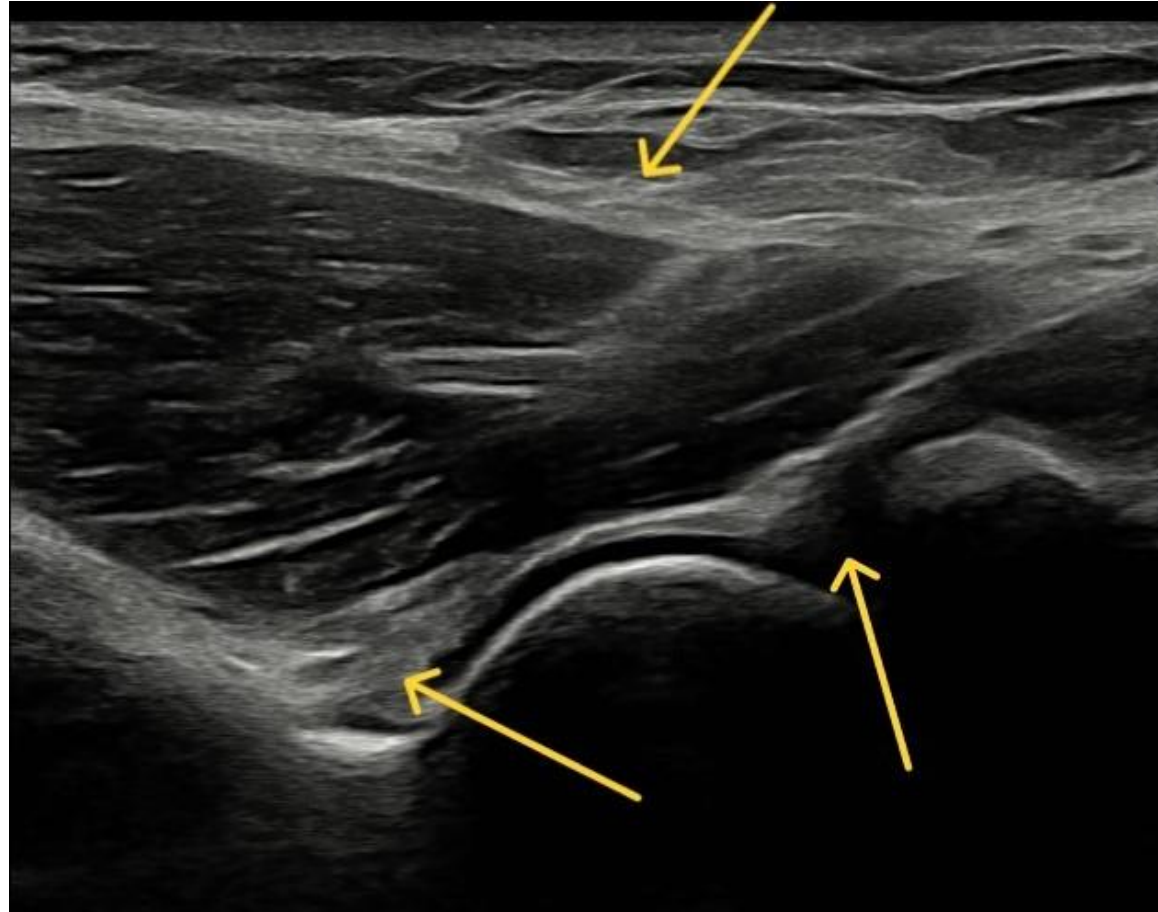
Mediale albue

Felles fleksorsene og mediale epikondyl



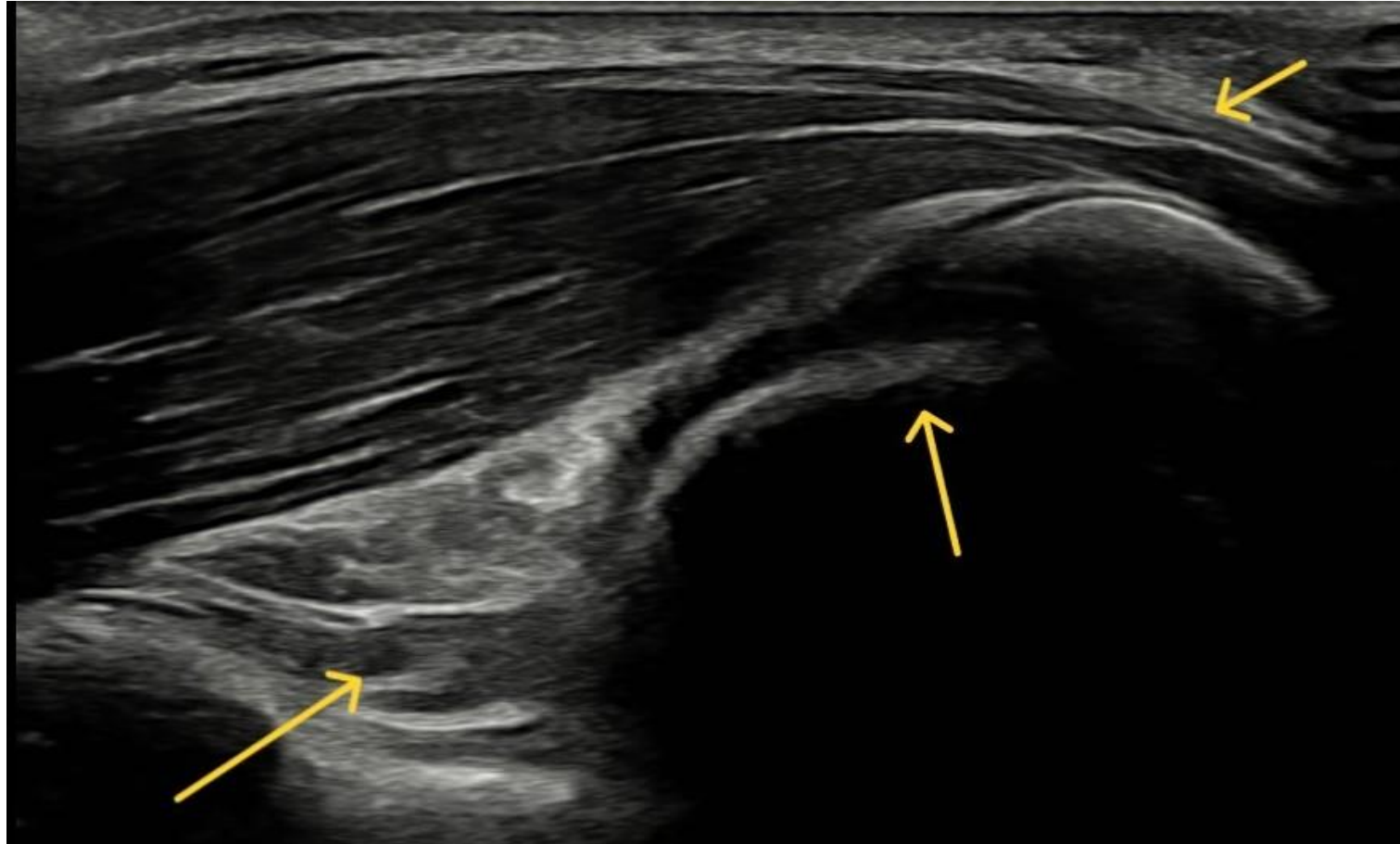
Fremre albue – lengdesnitt

Piler viser fremre synovialrecess, distale bicepsene og leddspalte (fra ve.mot hø.)

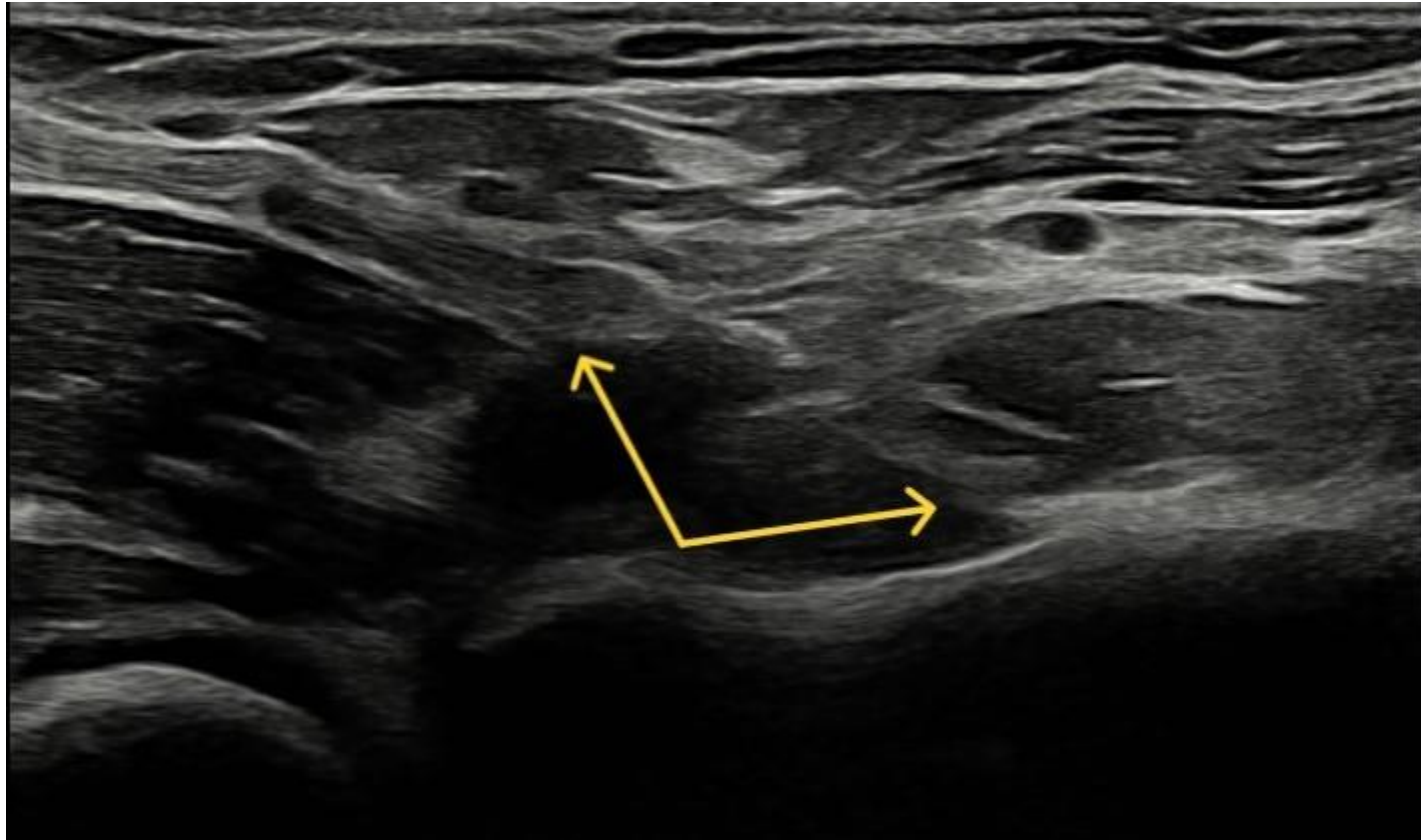

Bakre albue

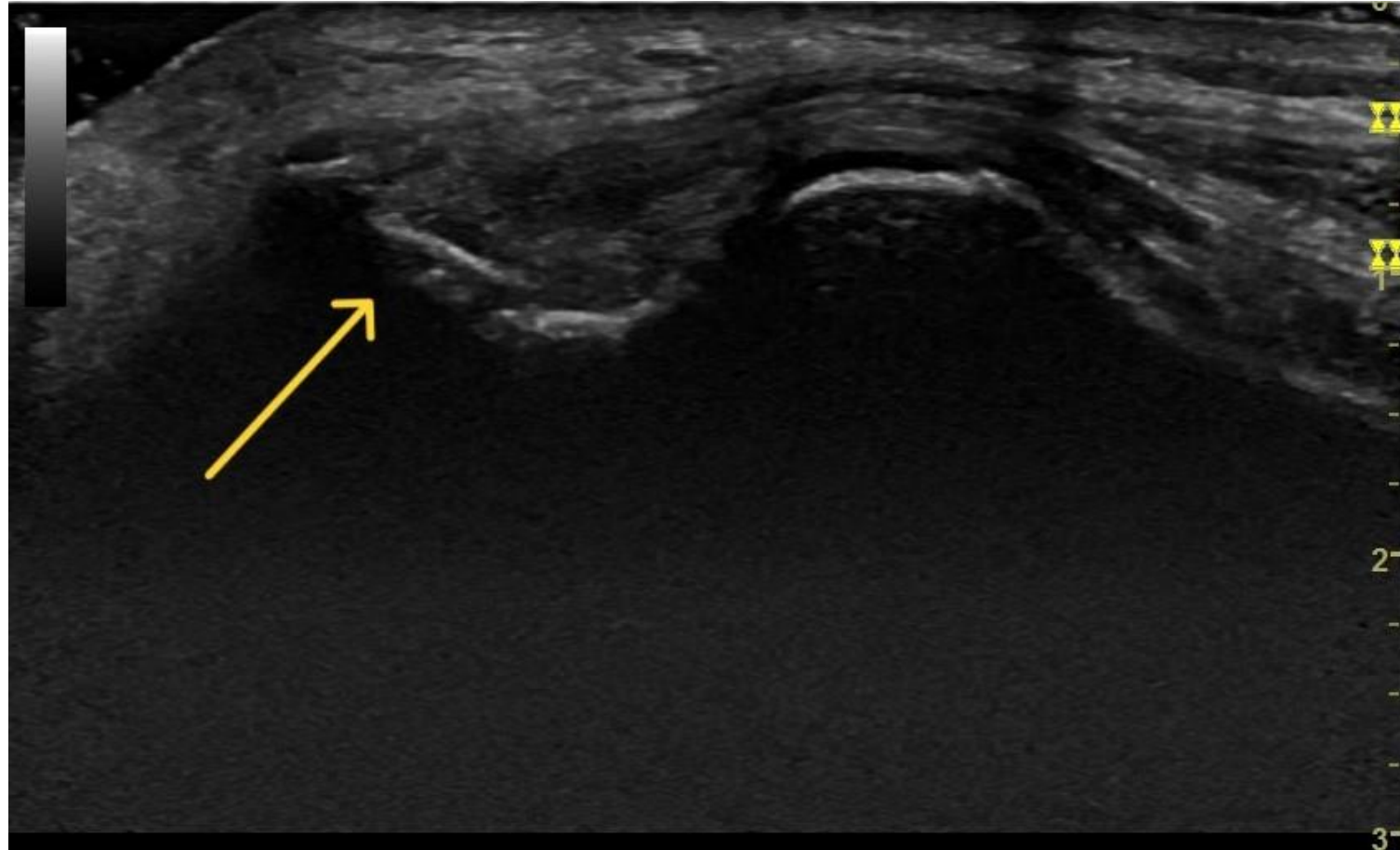
Olecranon fossa med bakre recess, trochlea-ulnarleddet og tricepssene hhv.



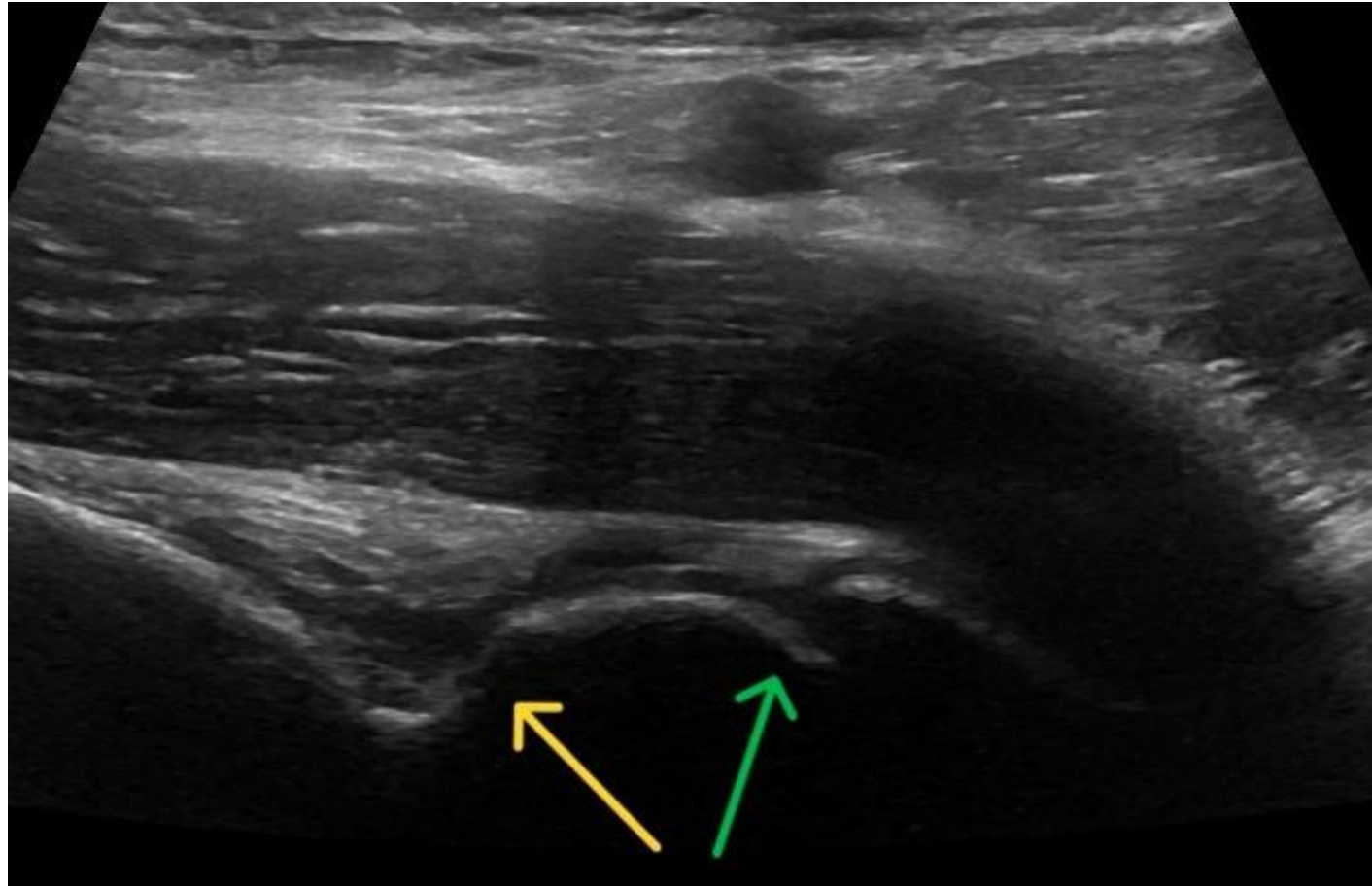
Distale bicepssenefeste



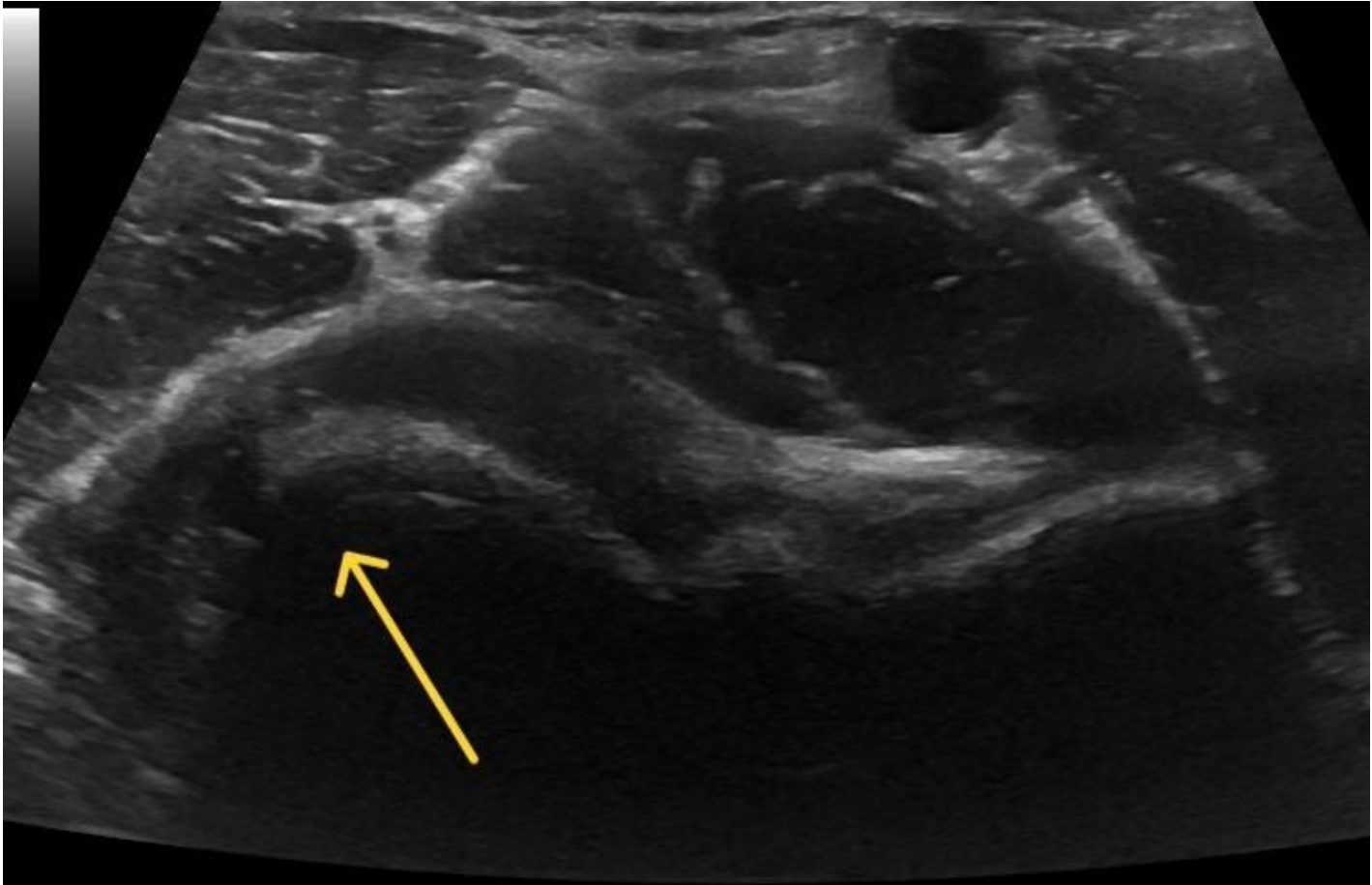
Ekstensorsenetendinose



Lett synovitt fremre recess hos håndverker uten kjent leddsykdom
Coronoid fossa med synovitt, gul pil. Trochlea-ulnarleddet, grønn pil

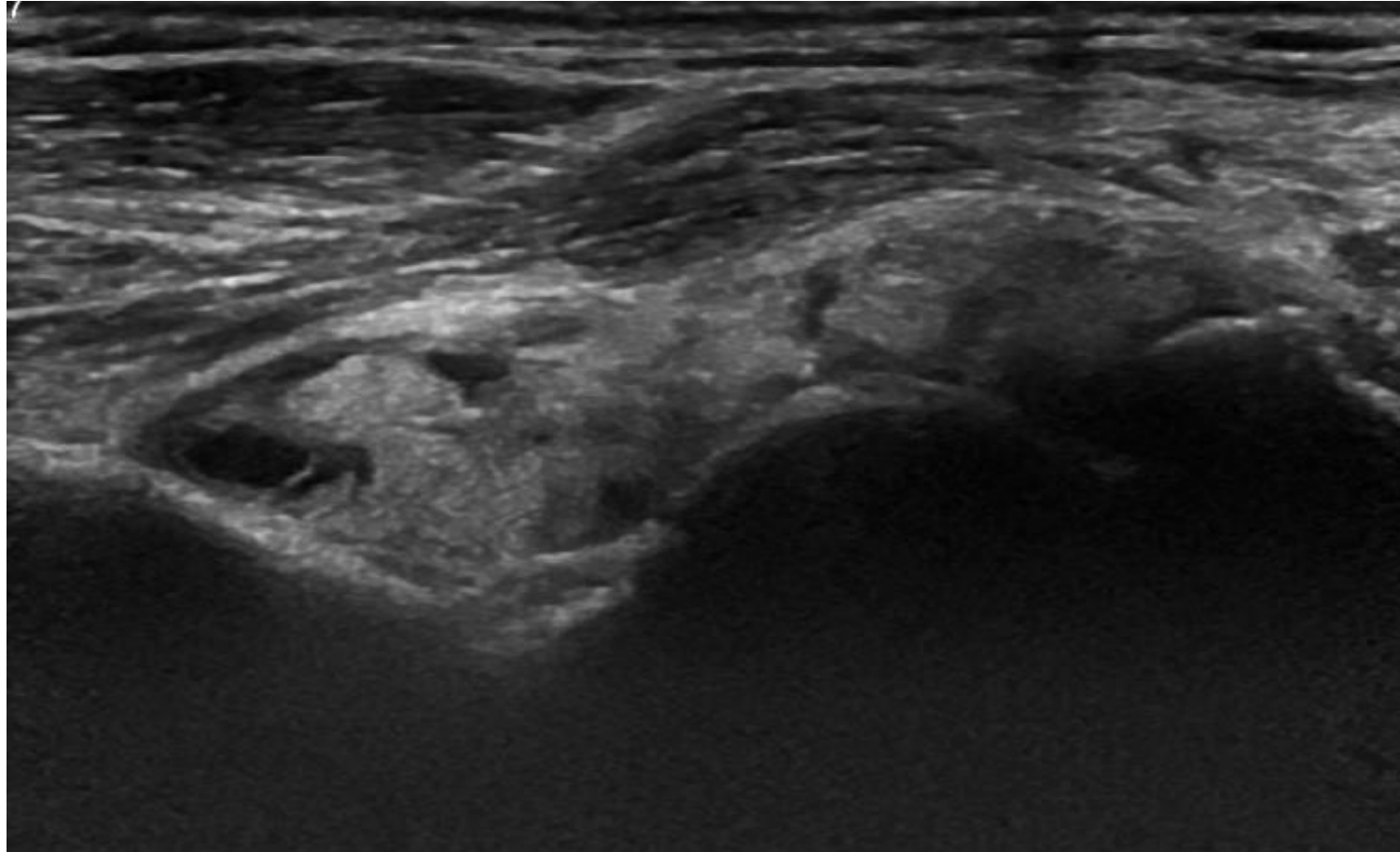


Samme pasient med synovitt lateralt i albueleddet ved tverrsnitt anteriort.



Pasient med artrose

Lengdesnitt fortil med betydelig synovitt fremre recess



Samme pasient med synovitt bakre recess i olecranon fossa, gul pil
Trochlea-ulnarleddet, grønn pil

