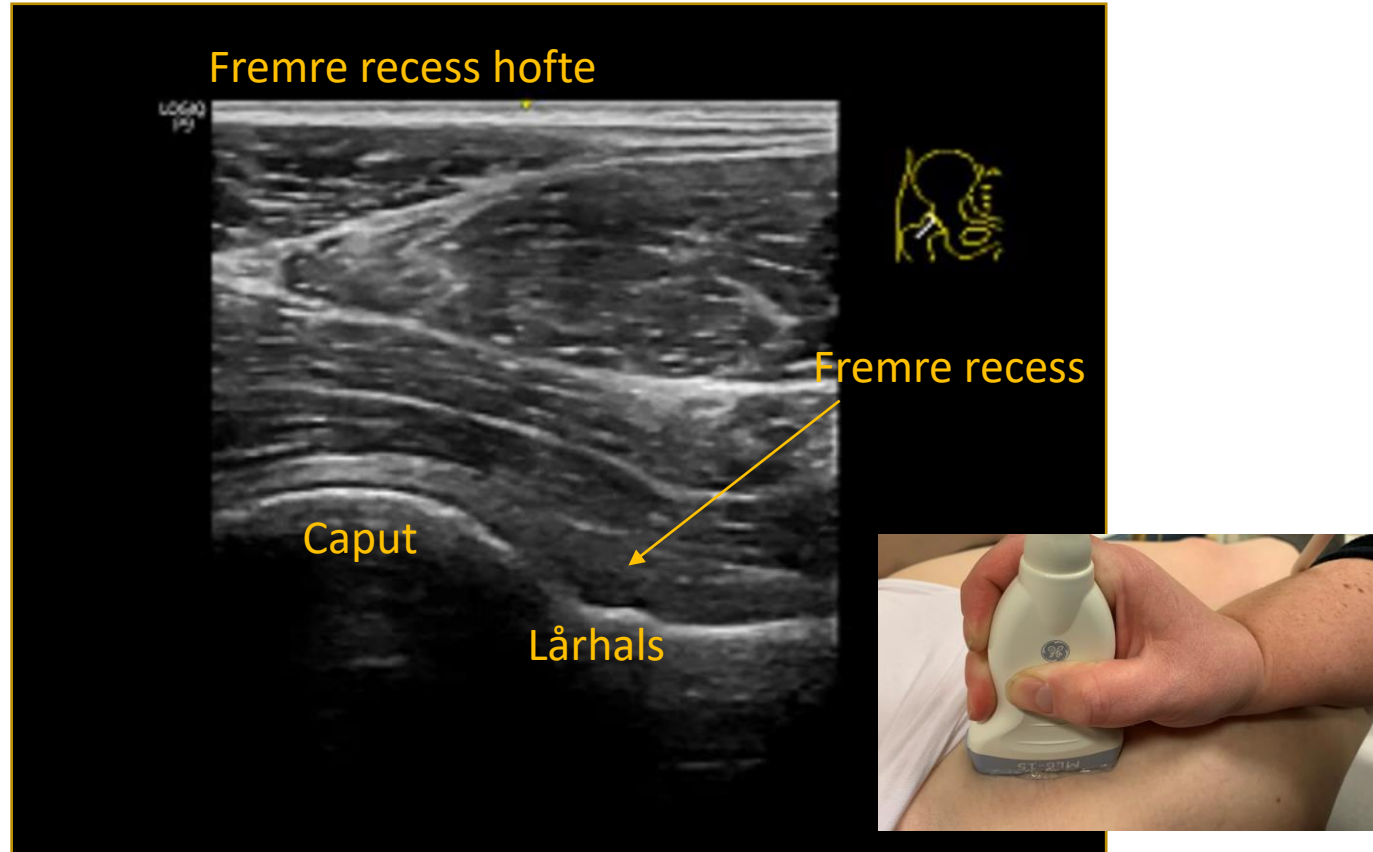
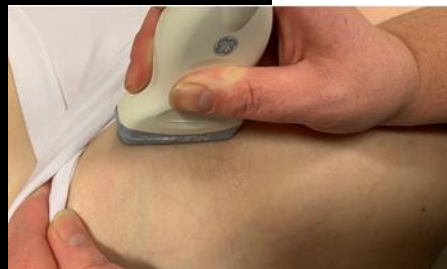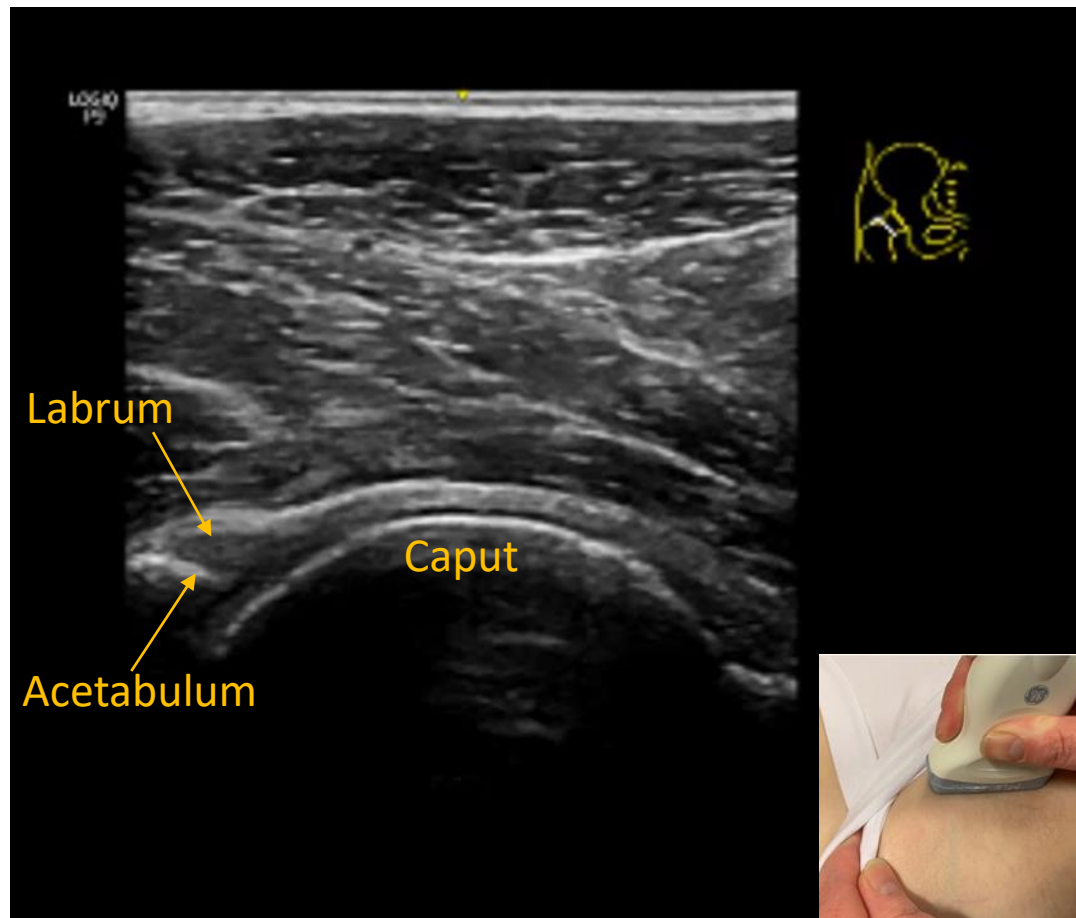
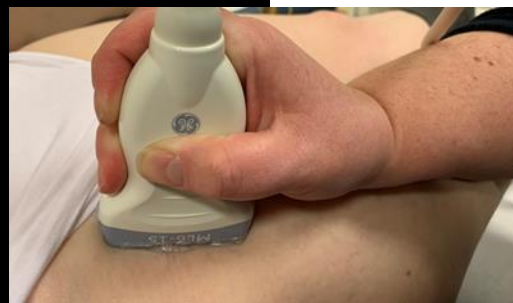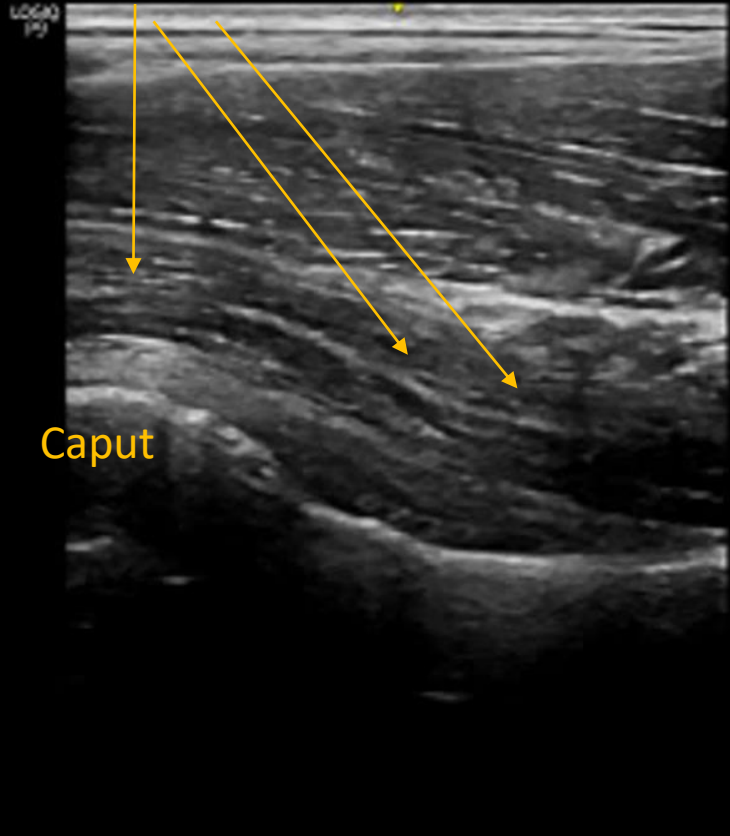


Ultralydundersøkelse hofte

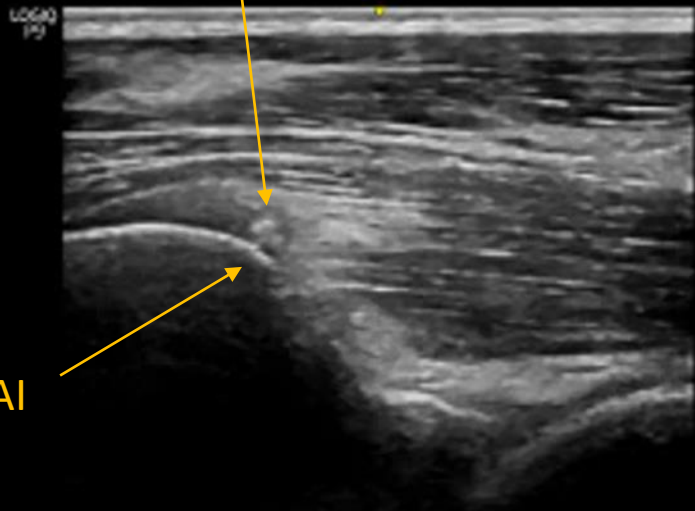




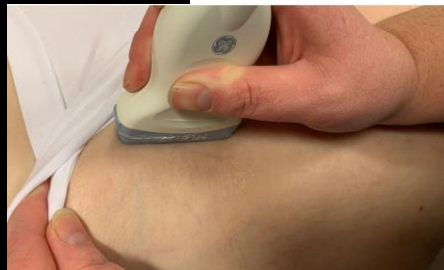Psoas lengdesnitt



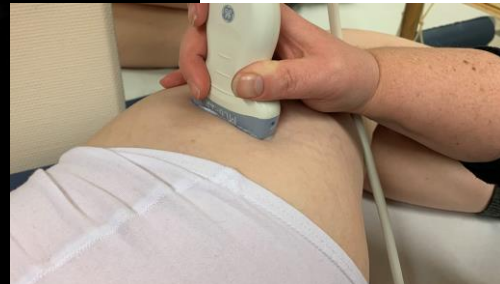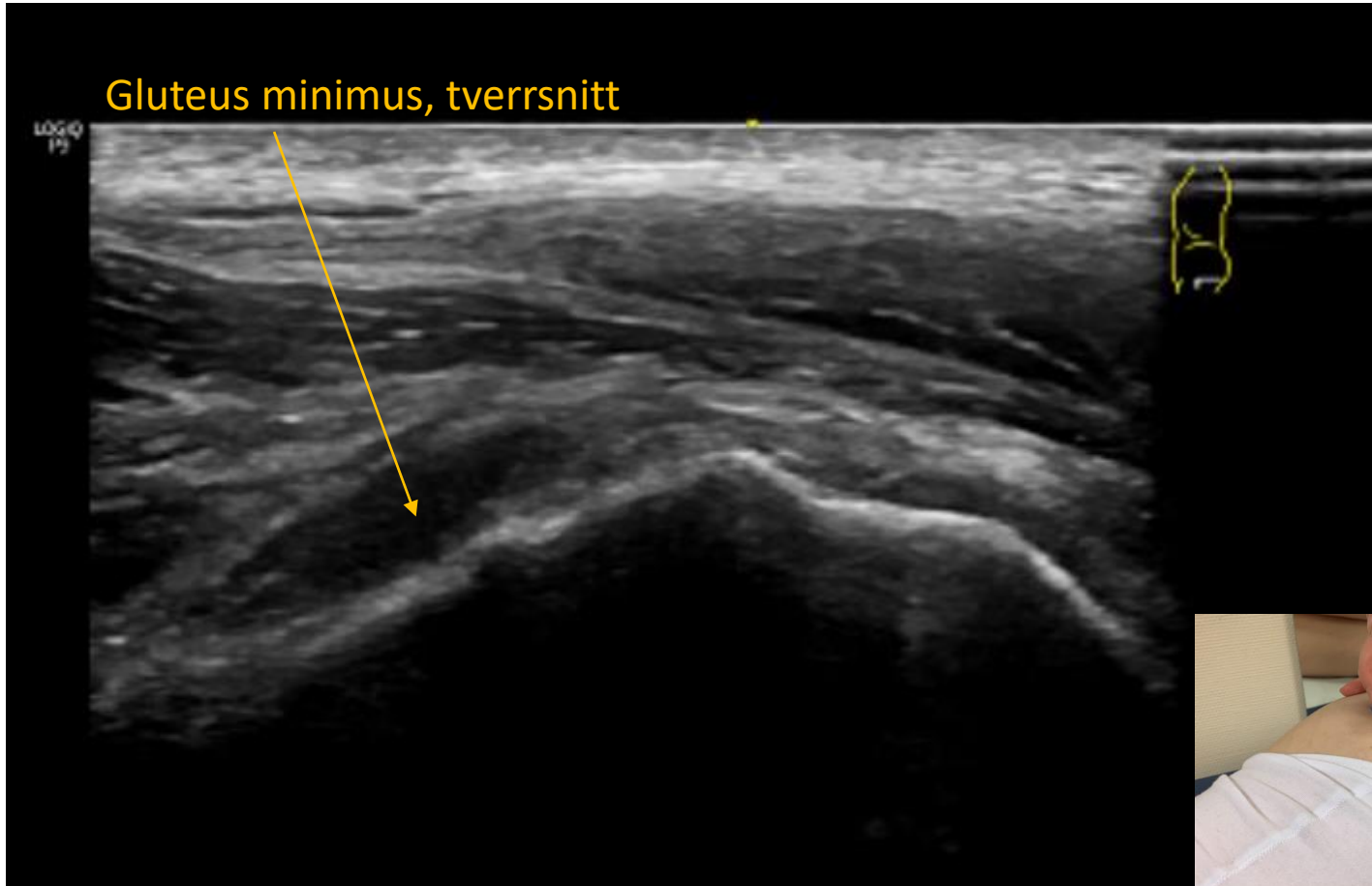
Rectus femoris innfesting

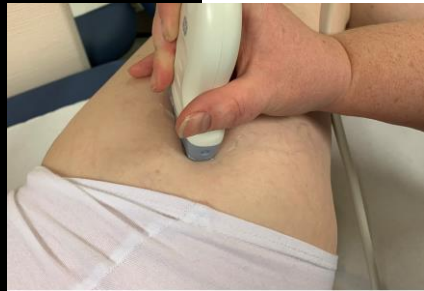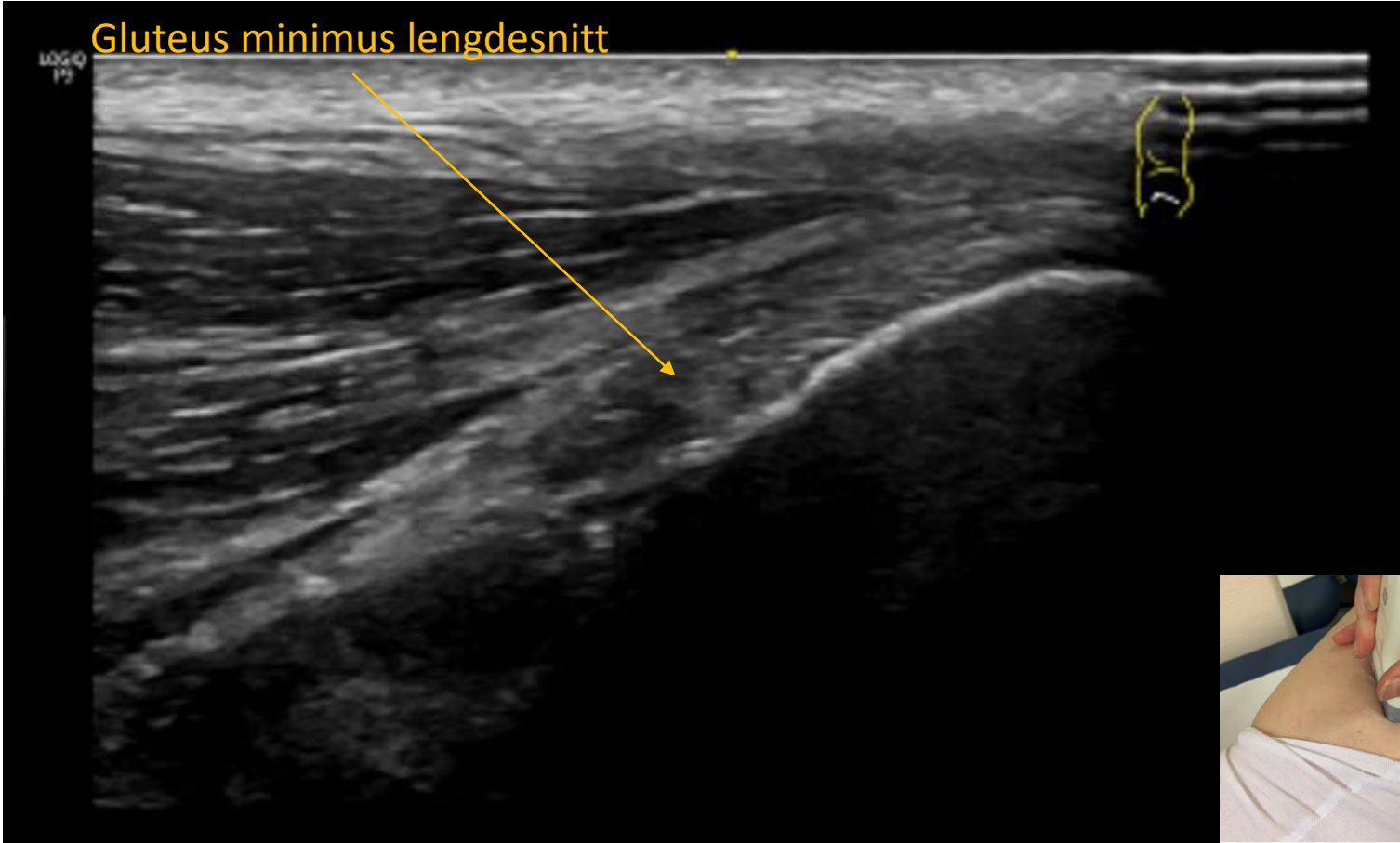


SIAI

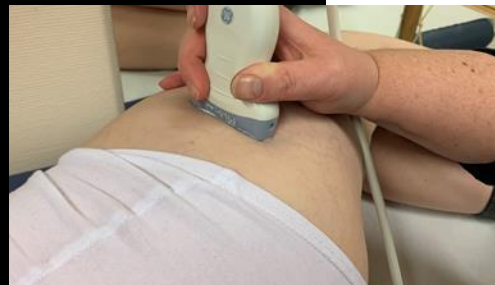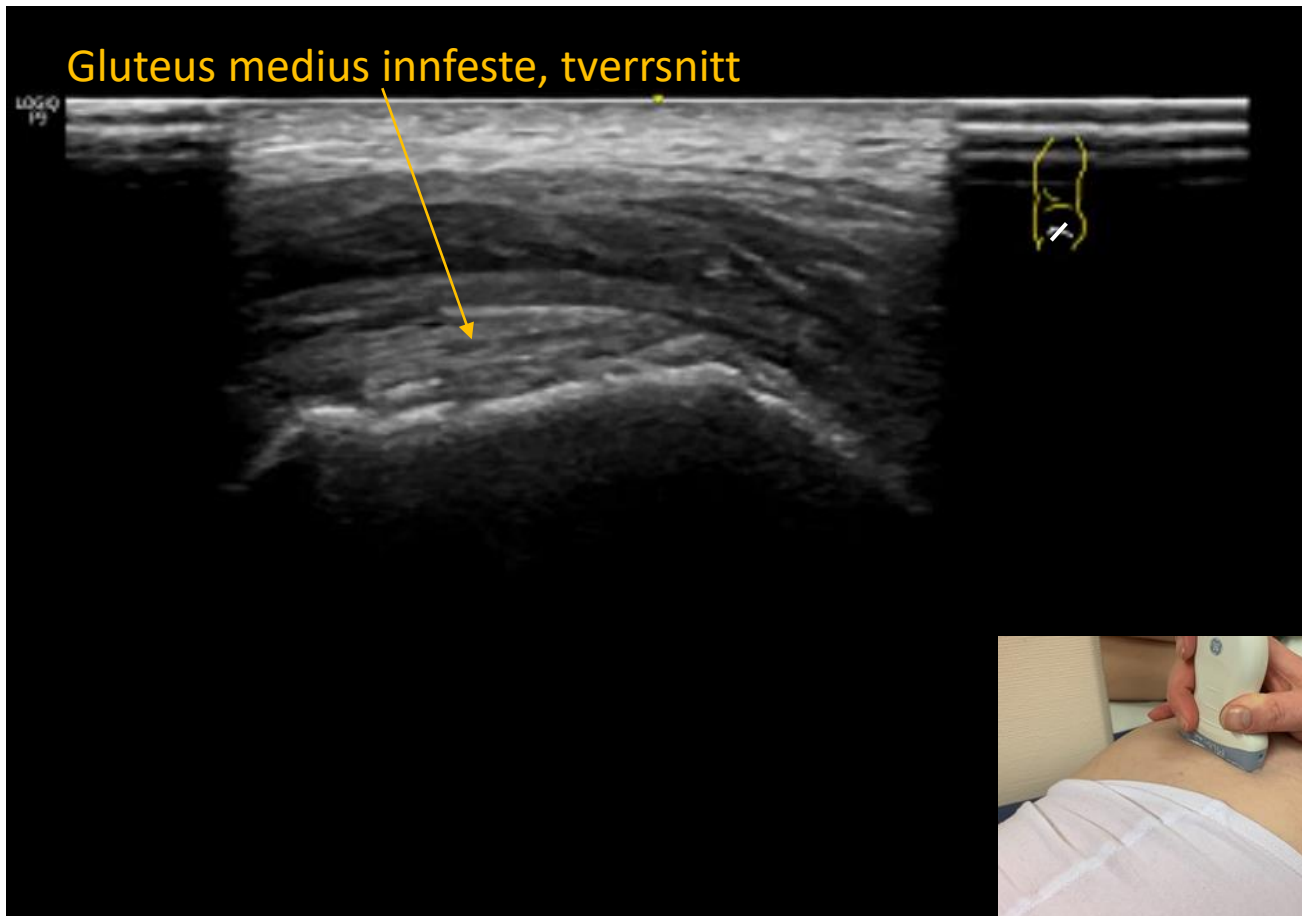


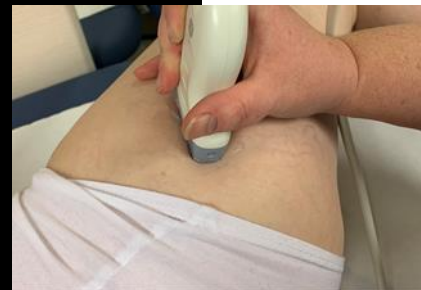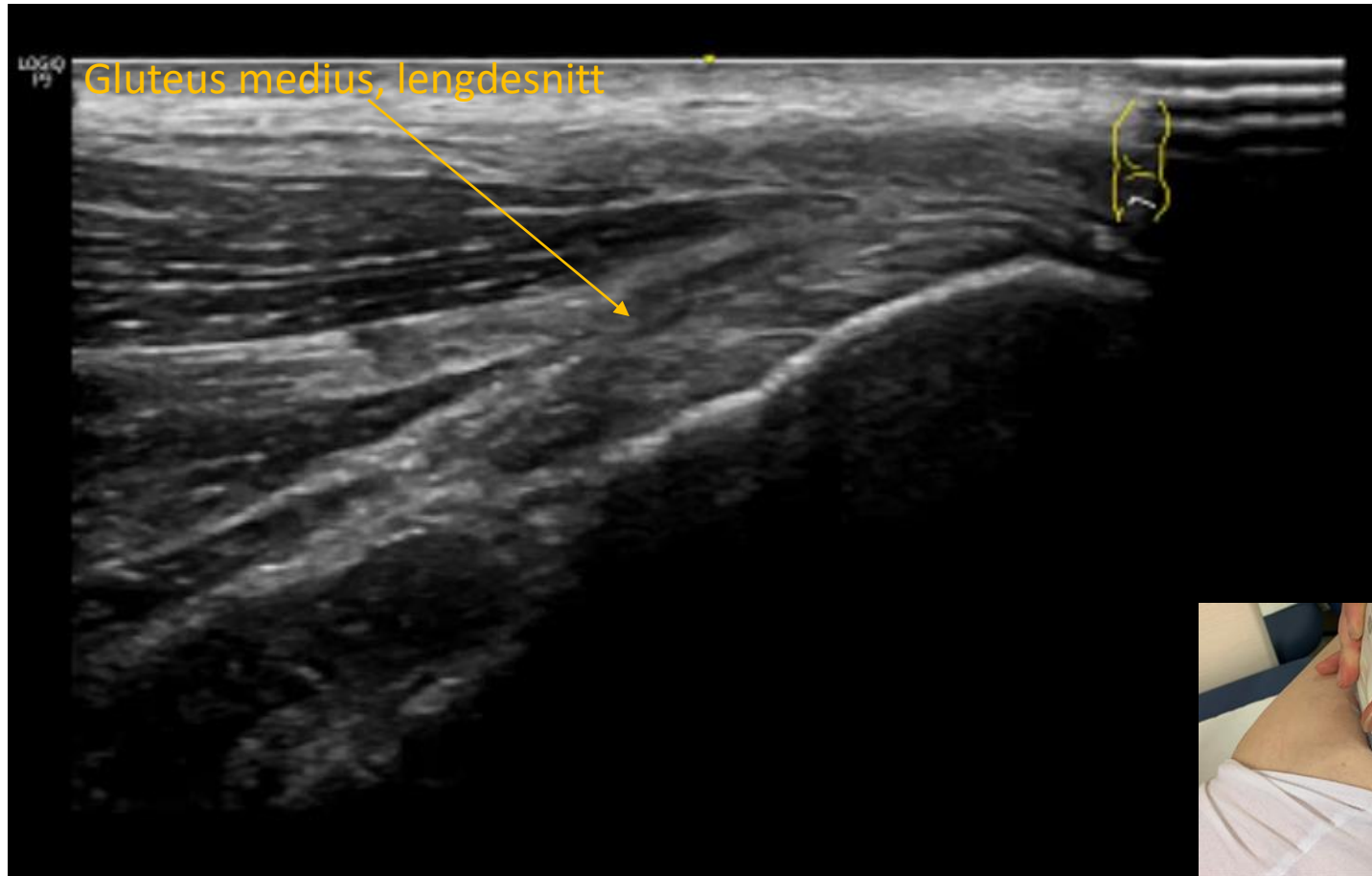
Gluteus minimus, tverrsnitt



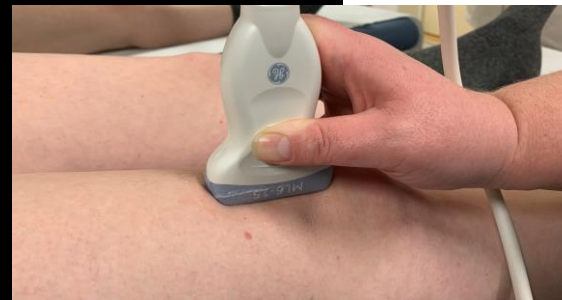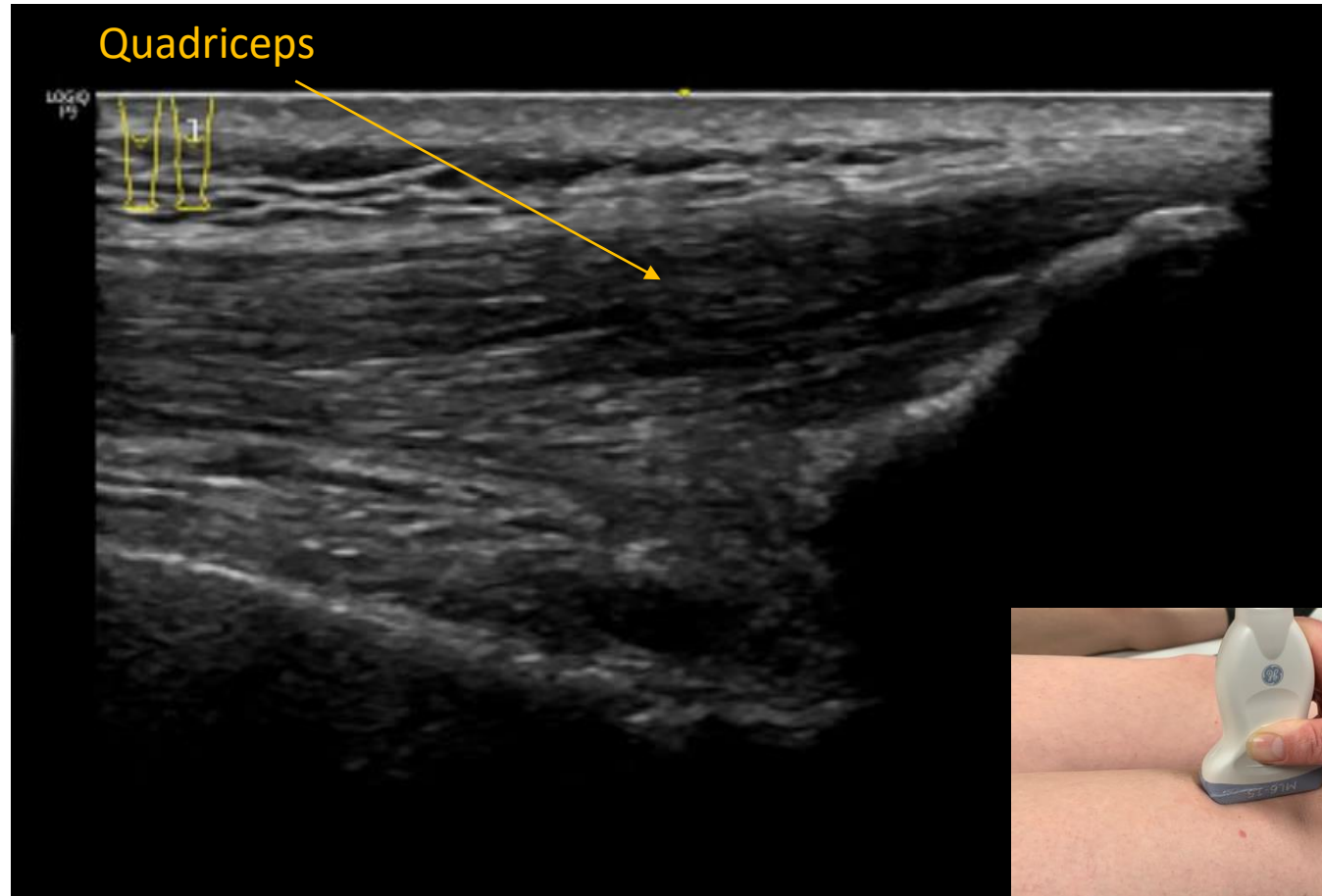


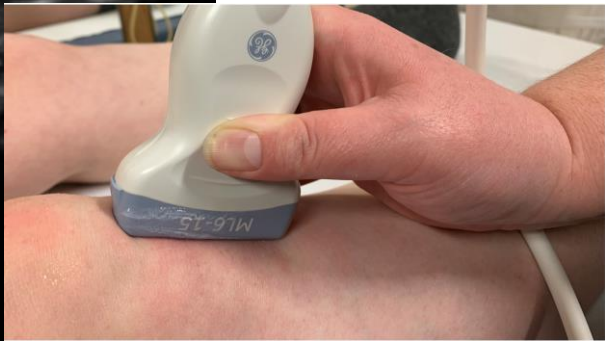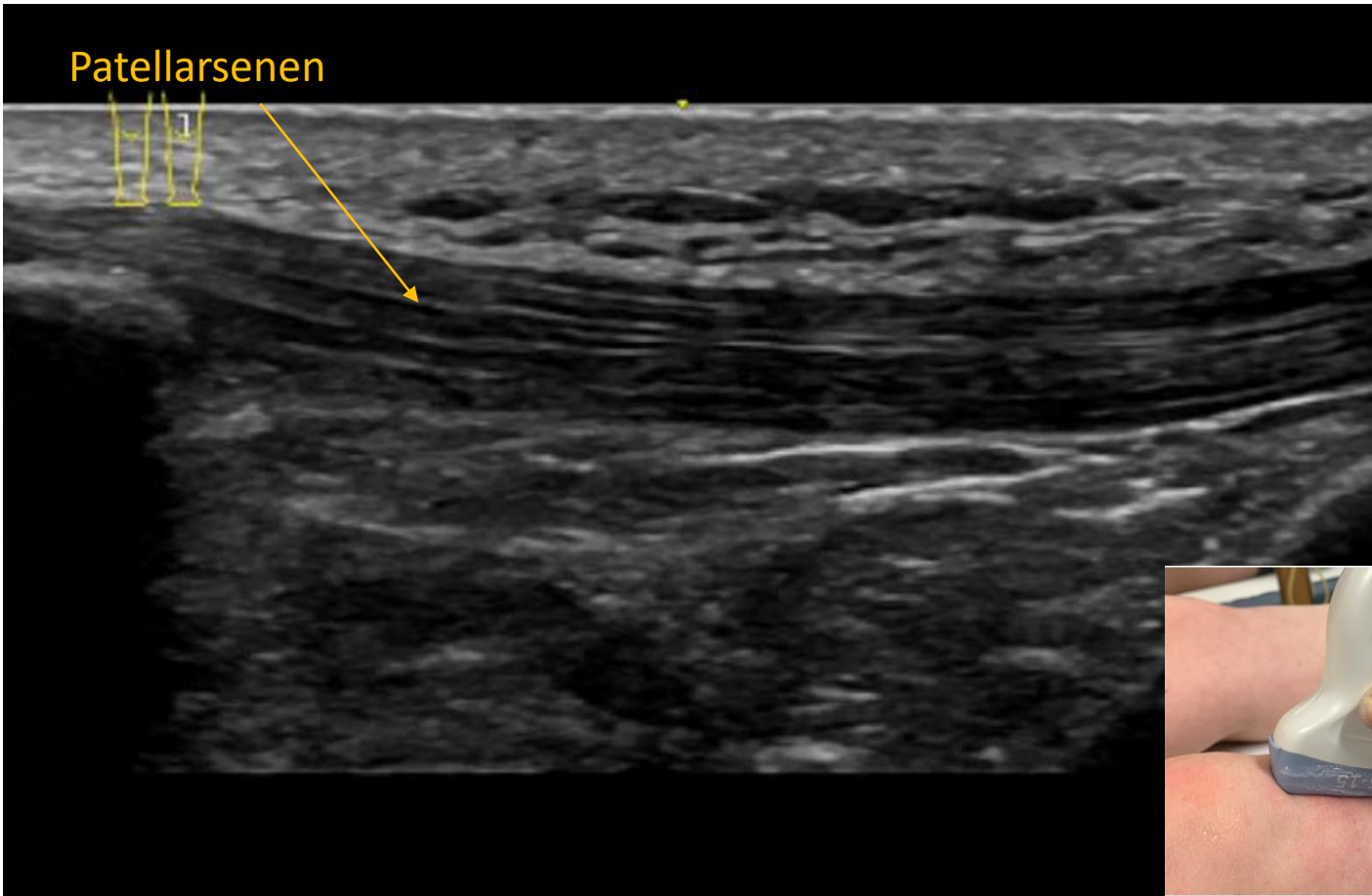
Gluteus medius innfeste, tverrsnitt





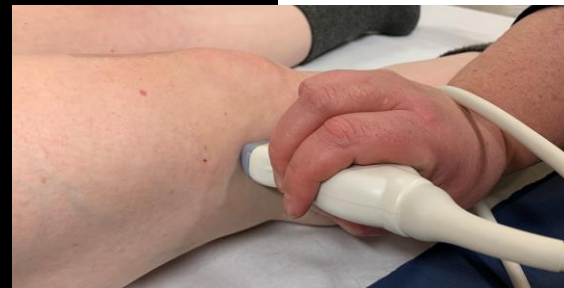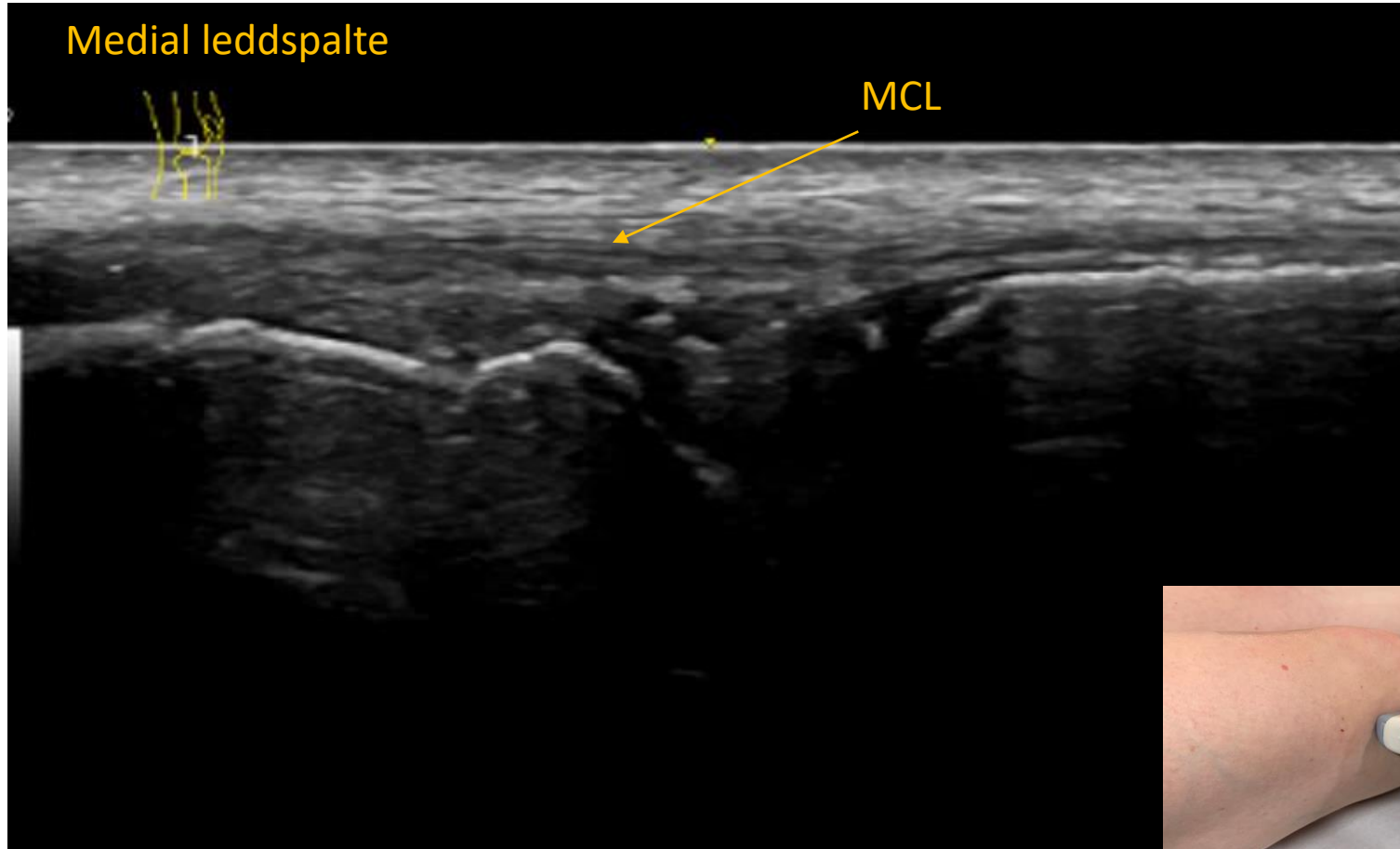
Ultralydundersøkelse kne

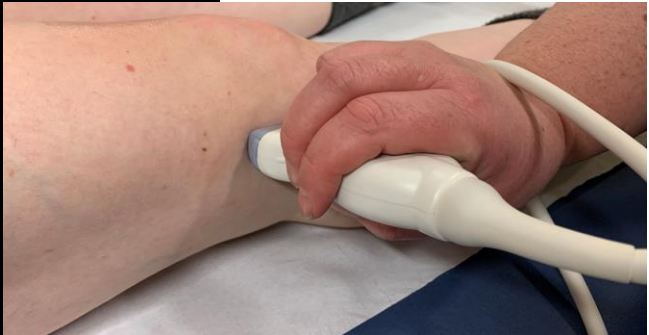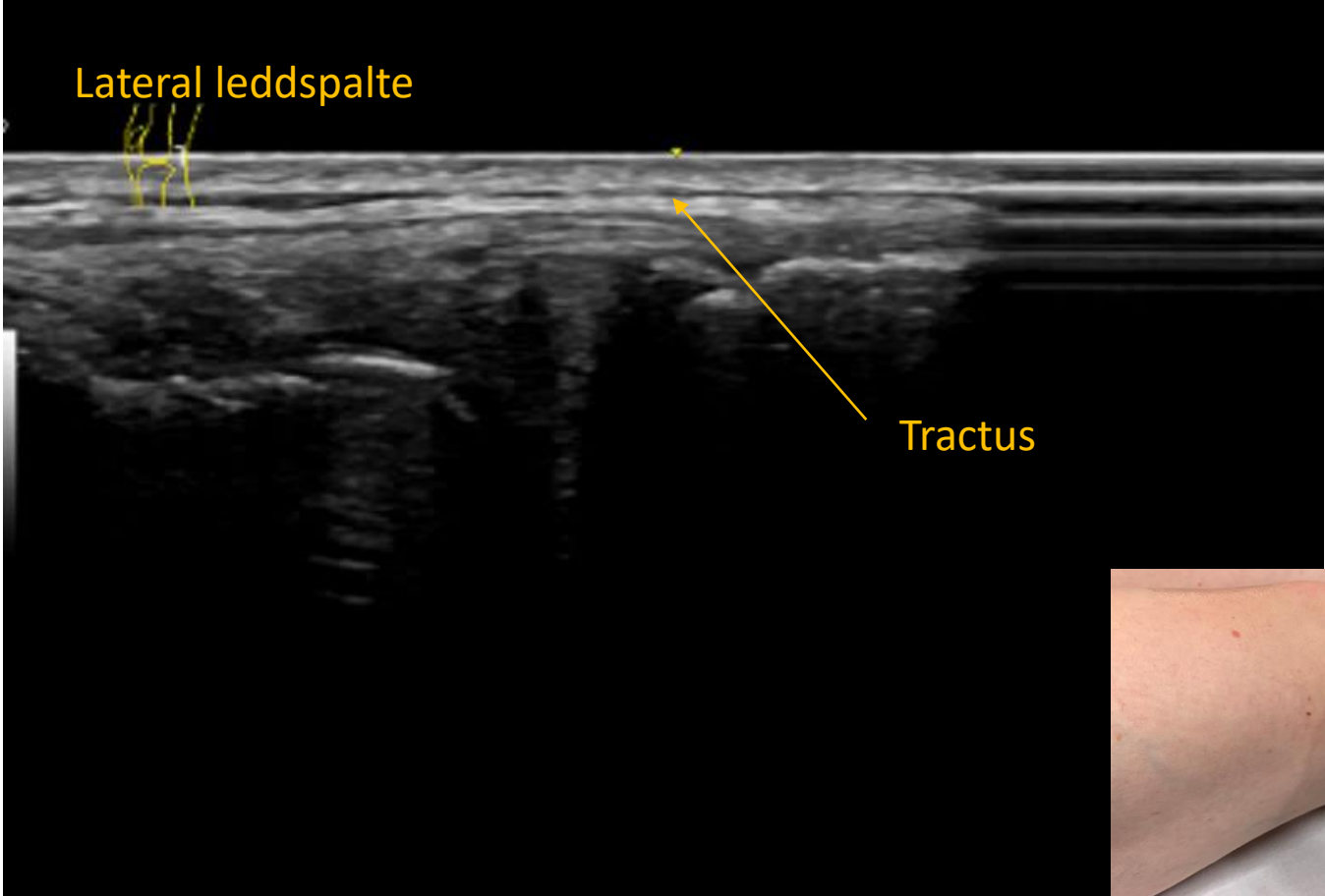




Medial leddspalte

MCL





Medial kneease (uten Bakers cyste)

